

**ORIGINAL ARTICLE**DOI: <https://doi.org/10.3329/mediscope.v11i2.76378>**Expression of p53 Protein in Different Grades of Gastric Carcinoma****\*R Karim<sup>1</sup>, S Afroz<sup>2</sup>, SN Karim<sup>3</sup>, F Nusrat<sup>4</sup>, N Sermin<sup>5</sup>, S Sen<sup>6</sup>, US Shabnam<sup>7</sup>, T Islam<sup>8</sup>****Abstract**

**Background:** Mutation in the TP53 suppressor gene and accumulation of p53 protein are the common genetic events in gastric carcinomas. This mutation has been associated with abnormalities in cell cycle regulation, DNA repair and synthesis, apoptosis, and suggested to be implicated in the prognosis of gastric carcinoma. **Objectives:** To assess the immunohistochemical expression of p53 protein in gastric carcinoma and to study the association of p53 protein expression with different histopathological grade of gastric carcinoma. **Methods:** In this cross-sectional observational study, 60 paraffin blocks of gastric adenocarcinoma were re-evaluated and histopathological grading were assessed. The p53 expression in the tumour cell nucleus of the submitted blocks were assessed by standard immunoperoxidase method. Appropriate positive control was run for each batch of slides. **Results:** Out of 60 cases, most of them 35 cases were poorly differentiated carcinoma, of which 28(80%) showed high expression and 7(20%) showed low expression of p53 protein. Twenty cases were moderately differentiated carcinoma, of which 12(60%) showed high expression and 8(40%) low expression. Only 5 were well differentiated carcinoma and all of which showed low expression of p53 protein. So, it was seen that with advancing grade of tumor, frequency of high expression of p53 protein was high and yielded statistically significant result (p value = 0.001). **Conclusion:** There was a significant association between immunohistochemical expression of p53 protein and histopathological grading of gastric adenocarcinoma. These results indicate that immunohistochemical expression of p53 protein is an important prognostic factor of gastric adenocarcinoma, allowing the selection of a group of patients with an extensive therapeutic indication.

**Keywords:** Gastric adenocarcinoma, p53 protein, Immunohistochemical expression.

**Introduction**

Carcinoma of the stomach is one of the leading causes of cancer death. World-wide gastric carcinoma (GC) ranks fourth in frequency and third in cancer mortality rate. The incidence of GC in Bangladesh is 5.2 per 100000.<sup>1</sup> Gastric carcinoma is a multi-factorial disease. Several risk factors have been identified in the etiology of gastric carcinoma.<sup>2</sup> Genetic factors are also important but imperfectly elucidated.<sup>3</sup>

The TP53, tumour suppressor gene is thought to play a crucial role in the process of gastric carcinogenesis.<sup>4</sup>

The p53, is a tumour suppressor protein that plays a vital role in regulation of genomic stability by controlling cell cycle, DNA repair and inducing apoptosis or cellular senescence when cell damage is beyond repair.<sup>5</sup> MDM2, a p53 specific E3 ubiquitin ligase, is the principal cellular antagonist of p53. In non-stressed healthy cells MDM2 ubiquitinylates p53, leading to its degradation by the proteasome. As a result, in healthy cell, nuclear accumulation is usually not detectable due to the short half life time (5-10min) of the wild type p53 protein. In stressed cell p53 is released from the inhibitory effect of

1. Dr. Rezwana Karim, Associate Professor, Department of Pathology, US-Bangla Medical College & Hospital, Narayanganj, Bangladesh. Email: badhanroni@gmail.com
2. Dr. Sadia Afroz, OSD, DGHS, Ministry of Health and Family Welfare, Dhaka, Bangladesh.
3. Dr. Syeda Noorjahan Karim, Associate Professor, Department of Pathology, Gazi Medical College, Khulna, Bangladesh.
4. Dr. Faiza Nusrat, Assistant Professor, Department of Pathology, East West Medical College, Dhaka, Bangladesh.
5. Dr. Nafisa Sermin, Clinical Pathologist, Department of Clinical Pathology, Dhaka Medical College, Dhaka, Bangladesh.
6. Dr. Sampurna Sen, Associate Professor & Head, Department of Pathology, Ad-din Sakina Women's Medical College, Jashore, Bangladesh.
7. Dr. Umme Salma Shabnam, Assistant Professor (Histopathology), Department of Histopathology, National Institute of Cancer Research and Hospital, Dhaka, Bangladesh.
8. Dr. Tasmia Islam, Specialist-pathology, Square Hospitals Ltd, Dhaka, Bangladesh.

MDM2. The majority of human carcinoma demonstrate bi-allelic loss of function mutations in TP53 gene. With loss of p53 function, the cell marches blindly along a dangerous path leading to malignant transformation.

Missense mutation within the TP53 gene results in protein that is stabilized through post transcriptional modification and accumulation within the cell nucleus. Thus, the immunohistochemical detection of mutated protein products can be possible.<sup>6</sup> The nuclear staining of p53 protein can be seen in both intestinal and diffuse type gastric carcinoma though commoner in intestinal type. The mutational spectrum of p53 in gastric carcinoma is wide. Previous reports suggested that over expression of p53 in gastric carcinoma is associated with bad prognosis. Furthermore, immunohistochemical evaluation of p53 protein may have an important prognostic value as there was reduced survival at five years for patients with p53 positive gastric carcinoma than p53 negative carcinoma. Previous studies also suggested that over expression of p53 protein is directly related to enhanced proliferative activity and increased propensity of poorly differentiated gastric carcinoma, representing greater tumour aggressiveness.<sup>7</sup>

Restoring functions of p53 would be a major step in curing gastric carcinoma. Especially the ability of TP53 to control apoptosis in response to DNA damage has important practical therapeutic implications to enhance the effect of radiation and chemotherapy. Evaluating the effect of adenovirus mediated reintroduction of wild type TP53 or modulation of MDM2 protein for induction of apoptosis as a potential clinical utility in gene therapy of gastric carcinoma, is a promising field in near future in the prevention of gastric carcinoma.<sup>9</sup> A preoperative assessment of p53 expression could be helpful in identifying patients with high risk of higher grade and more advanced tumours. Hence, evaluation of expression of p53 protein or alterations in its encoded TP53 gene may provide promising applications for diagnosis, prognosis, or therapeutic targets for gastric carcinoma.<sup>7</sup>

### Materials and methods

It was a cross-sectional observational study carried out from September, 2017 to June, 2019 at the Department of Pathology, Bangabandhu Sheikh Mujib Medical University (BSMMU), Dhaka, Bangladesh. The studied materials were paraffin blocks of gastric tissues, were taken from 60 patients underwent partial or total gastrectomy in the Department of Surgery & were diagnosed as gastric adenocarcinoma in Pathology Department, BSMMU.

Cases were re-evaluated and tumor grading was assessed. The p53 expression in the tumour cell nucleus of the submitted blocks were assessed by standard immunoperoxidase method using an automatic DAKO immunostainer at immunohistochemistry laboratory, Department of Pathology, BSMMU. The result of p53 protein immunohistochemistry was quantified as immunoreaction score (IRS) (Table 01). Appropriate positive control was run for each batch of slides. The statistical analysis was carried out using the Statistical Package for Social Sciences for Windows (SPSS-22). Continuous variable was expressed as Mean  $\pm$  SD. Categorical variable was presented by frequency and percentage. The association between the histopathological grading of malignancy, and nuclear expression of p53 protein was evaluated with Chi-Square ( $\chi^2$ ) test. A p-value of  $< 0.5$  was considered as statistically significant.

**Table 01: Immunoreaction scoring for P53 protein<sup>9</sup>**

IMMUNOREACTION SCORE (IRS)			
Percentage of p53 positive cells	Score	Staining intensity	Score
$\leq 10\%$	1	Negative	0
11- 49%	2	Weak	1
50- 79%	3	Moderate	2
$\geq 80\%$	4	Strong	3
<b>IRS score = Percentage of p53 positive cells <math>\times</math> Staining intensity</b>			
<b>Total score = 0 to 12 {<math>\leq 6</math> = low and <math>&gt;6</math> = high}</b>			

### Results

Age of the patients ranged from 22 to 80 years and mean  $\pm$  SD was  $53.43 \pm 12.12$  years. The highest number of cases (30%) belonged to 51-60 years age group. Among 60 cases, 37 were males and 23 were females with a male/female ratio of 1.6:1 (Table 02).

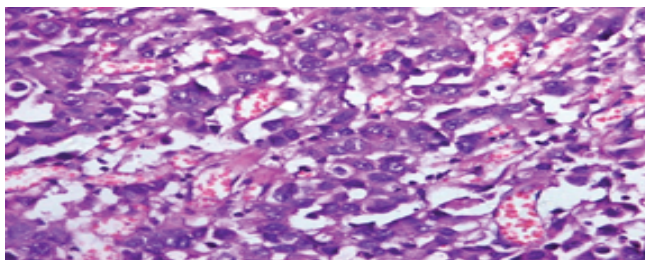
**Table 02: Age distribution of the patients (n=60)**

Age group (years)	Frequency	Percentage (%)
20-30	4	6.7
31-40	6	10.0
41-50	16	26.7
51-60	18	30.0
61-70	13	21.7
71-80	3	5.0
Total	60	100.0
Mean $\pm$ SD Range	$53.43 \pm 12.12$ (22 – 80) years	

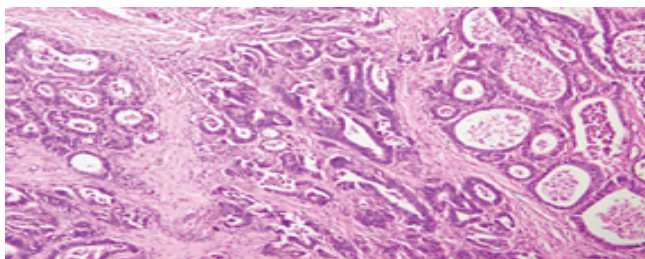
According to the tumour grading of cases, most of them, 35 were poorly differentiated carcinoma, of which 28(80%) showed high expression, and 20 cases were moderately differentiated carcinoma, of which 12(60%) showed high expression, and Only 5 were well-differentiated carcinoma, all of which showed low expression of p53 protein (Figure 1,2,3,4,5,6). So, it was observed that with advancing grade of tumor, frequency of high expression of p53 protein was high and yielded statistically significant result (p value = 0.001).

**Table 03: Association between nuclear expression of p53 protein and tumour grading of gastric adenocarcinoma cases (n=60)**

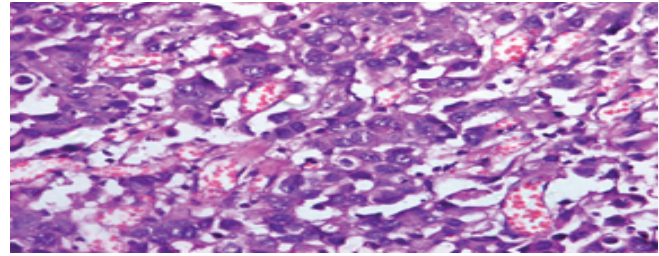
Tumour grading	No of cases	Nuclear expression of p53 protein		p-value
		High expression No. (%)	Low expression No. (%)	
Well-differentiated	5	0(0.0%)	5(100.0%)	0.001*
Moderately differentiated	20	12(60.0%)	8(40.0%)	
Poorly differentiated	35	28(80.0%)	7(20.0%)	
Total	60	40(66.7%)	20(33.3%)	



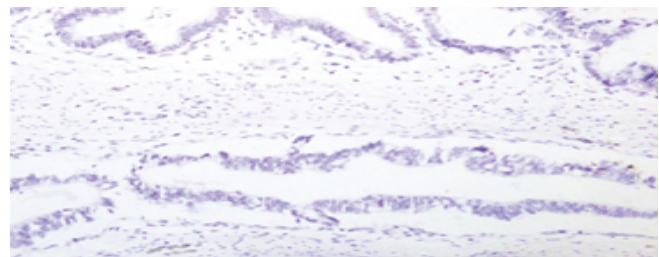
**Figure 01: Photo micrograph of a case of intestinal type of well differentiated adenocarcinoma (Case no 38, H&E stain, x100)**



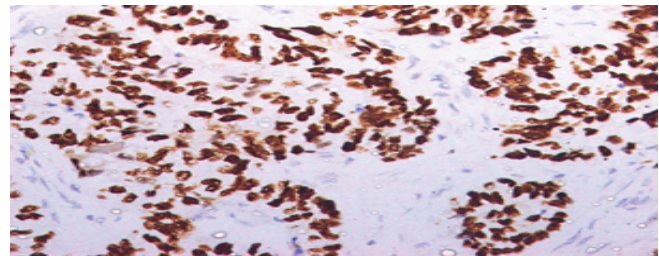
**Figure 02: Photomicrograph of a case of intestinal type moderately differentiated adenocarcinoma (case no.26, H&E stain, x200) adenocarcinoma**



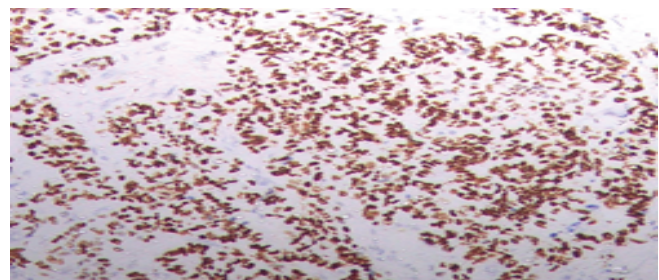
**Figure 03: Photo micrograph of a case of intestinal type poorly differentiated adenocarcinoma (Case no 9, H&E stain, x400)**



**Figure 04: Photo micrograph shows low expression of p53 protein in well differentiated adenocarcinoma, intestinal type (Case no 15, IHC, x400)**



**Figure 05: Photo micrograph shows high expression of p53 in moderately differentiated adenocarcinoma, intestinal type (Case no 26, IHC, x400)**



**Figure 06: Photo micrograph shows high expression of p53 in poorly differentiated adenocarcinoma, intestinal type (Case no 42, IHC, x400)**

**Discussion**

Gastric carcinoma is a common tumour in the world. Although great efforts have been made in the field of early diagnosis and adjuvant therapy, the incidence and overall mortality of gastric carcinoma continue to increase. Since



gastric tumour cells commonly infiltrate into the wall of the stomach as well as lymph nodes through lymphatics, these are routinely used to identify a patient's prognosis, tumor stage, and treatment modality. The TP53 is a tumor suppressor gene, mutation in which plays an important role in tumorigenesis and progression of many carcinomas including gastric carcinoma. However, the relationship between p53 expression and tumor grading remains ambiguous.

This present study was carried out to evaluate the association of immunohistochemical expression of p53 protein in gastric carcinoma with tumour grading. It is a Cross-sectional observational study in which the studied materials were paraffin blocks of gastric tissues taken from 60 patients who underwent partial or total gastrectomy in the Department of Surgery from September 2017 to June 2019 and were diagnosed as gastric adenocarcinoma in the Department of Pathology, BSMMU. Cases were re-evaluated and tumor grading was assessed. Out of 60 cases, 40(66.7%) cases showed high expression of p53 protein, while 20(33.3%) cases showed low expression.

In consideration to tumor grade, this study showed that with advancing grade of tumor, frequency of high expression of p53 protein was high and yielded statistically significant result (Table 03). This result is similar to the study conducted by Lazar et al., (2008) in which out of 39 cases of poorly differentiated adenocarcinoma, 18(46.1%) cases showed high expression of p53 protein, 20 moderately differentiated adenocarcinoma, of which 7(35%) cases showed high expression of p53 protein and 2 well-differentiated adenocarcinoma, none of which showed high expression of p53 protein. They observed a significant association between the tumor grade and p53 expression ( $p$ -value = 0.039).<sup>4</sup> Another study done by Malini et al., (2016) in which out of 17 cases of poorly differentiated adenocarcinoma, 10(58.7%) cases showed high expression of p53 protein, 23 moderately differentiated adenocarcinoma, of which 10(43.4%) cases showed high expression of p53 protein and 5 well-differentiated adenocarcinoma, none of which showed high expression of p53 protein. They also observed statistically significant association between high expression of p53 protein and tumor grade ( $p$ -value = 0.049).<sup>10</sup> So, both of these studies showed significant association of p53 protein with tumour grading which is consistent with this present study.

### Conclusion

In this present study, there was a significant association of p53 protein expression with tumor

grade. A preoperative assessment of p53 expression could be helpful in identifying patients with high risk of higher grade and more advanced tumours. These results indicate that immunohistochemical evaluation of p53 protein is an important prognostic factor of gastric carcinoma, allowing the selection of a group of patients with an extensive therapeutic indication.

### References

1. WHO, 2018. [Online] Available at: <https://gco.iarc.fr/today/data/factsheets/population/50-bangladesh-factsheets.pdf> [Accessed 14 July 2019]
2. Rahman R., Asombang AW & Ibdah JA. Characteristics of gastric cancer in Asia. *World Journal of Gastroenterology*, 2014;20 (16): 4483-4490.
3. Williams NS, O'Connell PR, McCaskie A, Bailey & Love's Short Practice of Surgery, 2008. 27 ed. New Delhi: CRC press.
4. Lazar D, Taban S, Sporea I, Dema A, Cornianu M, Lazar E, Goldis A, Ratiu I and Vernic C. The immunohistochemical expression of the p53-protein in gastric carcinomas. Correlation with clinicopathological factors and survival of patients, 2010. *Rom J Morphol Embryol*; 51(2):249-257.
5. Yang P, Du CW, Kwan M, Liang SX, Zhang GJ. The impact of p53 in predicting clinical outcome of breast cancer patients with visceral metastasis. *Scientific Reports*. 2013.
6. Fenoglio-Preiser CM, Wang J, Stemmermann G. & Noffsinger A. TP53 and gastric carcinoma: a review, *Human mutation* 2003;21(3):258-270
7. Akshatha C, Mysorekar V, Arundhathi S, Arul P, and Shetty S. Correlation of p53 over expression with the clinicopathological prognostic factors in gastric adenocarcinoma. *International Journal of Biomedical and Advance Research*, 2016;7(7):310- 314.
8. Sankalecha TH, Gupta SJ, Gaikwad NR, Ughade SN. Correlation of p53 Expression with Various Clinicopathological Parameters of Gastric Carcinoma and Its Relationship with Survival. *Gastroenterology and Hepatology*, 2017;6(3): 2370-2375
9. Lauren P. The two histological main types of gastric carcinoma: diffuse and so-called intestinal-type carcinoma: an attempt at a histo-clinical classification. *Acta Pathologica Microbiologica Scandinavica*, 1965;64(1): 31-49
10. Malini KP, Srivani & Kumar OS. Study of expression of P53 in Gastric Carcinoma -As a prognostic indicator. *International Archives of Integrated Medicine*, 2016;3(11): 4-60.